

Otterbein University

Digital Commons @ Otterbein

Nursing Student Class Projects (Formerly MSN)

Student Research & Creative Work


Summer 2015

Thrombotic Thrombocytopenia Purpura

Ann Oliva

Otterbein University, ann.oliva@otterbein.edu

Follow this and additional works at: https://digitalcommons.otterbein.edu/stu_msn

 Part of the [Cardiovascular Diseases Commons](#), [Medical Pathology Commons](#), [Nursing Commons](#), and the [Pathological Conditions, Signs and Symptoms Commons](#)

Recommended Citation

Oliva, Ann, "Thrombotic Thrombocytopenia Purpura" (2015). *Nursing Student Class Projects (Formerly MSN)*. 77.

https://digitalcommons.otterbein.edu/stu_msn/77

This Project is brought to you for free and open access by the Student Research & Creative Work at Digital Commons @ Otterbein. It has been accepted for inclusion in Nursing Student Class Projects (Formerly MSN) by an authorized administrator of Digital Commons @ Otterbein. For more information, please contact digitalcommons07@otterbein.edu.

Thrombotic Thrombocytopenia Purpura

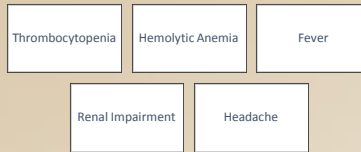
Ann Oliva BSN, RN, OCN

Otterbein University, Westerville, Ohio

Introduction

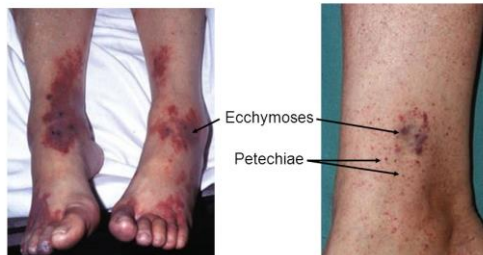
Patients with Thrombotic Thrombocytopenia Purpura, or TTP, are often times seen in the emergency department and subsequently admitted to the inpatient or the critical care unit. The problems that TTP patients can present with vary greatly and astute nursing assessment plus knowledge of the pathophysiology behind the diagnosis is vital to deliver excellent nursing care. Thrombotic Thrombocytopenia Purpura or TTP is a rare but potentially fatal condition that occurs as result of decreased levels of ADAMTS-13, a cleaving protease for von Willebrand factor (vWF), which causes platelet aggregation and microvascular thrombi and subsequent end-organ damage, along with thrombocytopenia, hemolytic anemia, and possible neurologic and renal impairment (Kappler, Ronan-Bentle, & Graham, 2014). TTP belongs to a group of disorders called thrombotic microangiopathies. Also included in this group are Hemolytic Uremic Syndrome (HUS), and pregnancy-induced hemolysis, elevated liver enzymes, and low platelet count (HELLP) syndrome (Kappler et al., 2014). The decreases in ADAMTS-13, causing TTP, can either be congenital, idiopathic, or acquired as a result of autoantibodies, drugs, or malignancies (Trachtman, 2013). TTP can occur spontaneously or be triggered by an infection, pregnancy, or other stimulus of autoantibodies and as many as 30% of those affected relapse after a remission (Rosove, 2014). Most commonly occurring in adults, primarily women, patients typically present with thrombocytopenia (with or without signs of bleeding), hemolytic anemia, fever, altered mental status or headaches, renal impairment, and abdominal or chest pain (Kappler et al., 2014). Treatment for TTP is plasma exchange therapy, with the goal of replacing the missing ADAMTS-13 and removing the contributing antibody (Kappler et al., 2014). Patients presenting with these symptoms may be cared for in many areas of practice and because correct diagnosis and prompt treatment are crucial in TTP, clinicians must be informed on signs, symptoms, and proper treatment. Without prompt recognition and treatment, mortality rates from TTP can be as high as 90% (Kappler et al., 2014).

Signs and Symptoms



Patients presenting with TTP can exhibit many different symptoms due to the pathological processes of TTP. Classically, thrombocytopenia, microangiopathic hemolytic anemia, renal impairment, neurological impairment, and fever are seen, although not necessarily all together (Strecker-McGraw & Mark Andrew, 2011). Bleeding, petechiae, purpura, and ecchymosis related to thrombocytopenia can occur as well as jaundice or dark urine related to hemolytic anemia. Abdominal pain, chest pain, and neurological symptoms can present as a result of organ damage and microvascular thrombi (Kappler et al., 2014). Lab values will show anemia and thrombocytopenia with platelet counts typically between 20 and 50,000/mm³ (Kappler et al., 2014). The reticulocyte count may be elevated and schistocytes can be seen on peripheral smear. Hemolytic anemia will cause a decreased haptoglobin, elevated reticulocyte count, elevated LDH, and an elevated indirect bilirubin from intravascular hemolysis. Coagulation studies will be normal, differentiating TTP from disseminated intravascular coagulation or DIC. Kidney injury may be seen on a basic metabolic panel but is typically more severe in HUS (Kappler et al., 2014, Strecker-McGraw & Mark Andrew, 2011). Some patients will present with chest pain and elevated troponin levels thought to be related to thrombosis of the coronary vasculature and should have cardiac monitoring and enzyme levels to monitor for cardiac impairment (Kappler et al., 2014, Strobel, Gingold, & Calvello, 2014). The presenting signs and symptoms can vary in patients with TTP but current guidelines suggest treatment for TTP be initiated in patients with thrombocytopenia, and microangiopathic hemolytic anemia without other explanation (Strobel et al., 2014)

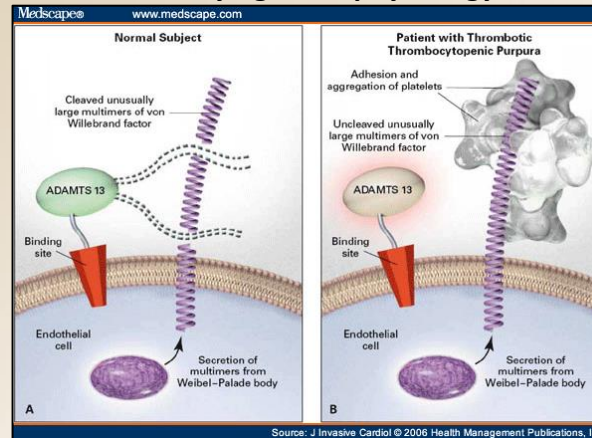
Examples of Purpura



American Academy of Dermatology

Retrieved from: <https://www.aad.org>

Underlying Pathophysiology



Retrieved from: http://www.medscape.com/viewarticle/542225_3

Platelets play a significant role in the formation of clots and the prevention of bleeding. The normal platelet count falls within the range of 150,000 to 450,000/mm³ (Konkle, Hauser, Longo, Jameson, & Loscalzo, 2015). When endovascular tissue is injured platelets adhere to the intimal surface via binding with vWF, present in both endothelial tissue and plasma, and intercellular signals leading to activation of platelet glycoprotein IIb/IIIa receptor and platelet aggregation (Konkle et al., 2015) Usually vWF is cleaved into smaller proteins by a plasma metalloprotease called a disintegrin and metalloproteinase with a thrombospondin type 1 motif member 13, or ADAMTS-13. In TTP however, the ADAMTS-13 concentration is very low either due to congenital abnormalities or acquired autoantibodies, which leaves large un-cleaved multimers of vWF that stimulate large aggregates of platelets, which can break off and occlude vessels (Rosove, 2014). Aggregation of platelets leads to organ damage and can result in neurologic, cardiac, and renal complications as well as bleeding complications. TTP is more common in pregnant women, patients with HIV infection, and can be induced by certain drugs or in patients who have undergone an organ or stem cell transplant (Konkle et al., 2015, Rosove, 2014)

Significance of Pathophysiology

The acute state of widespread microvascular thrombi and thrombocytopenia can lead to significant injury and precipitate poor outcomes for patients diagnosed with TTP. Patients are at risk for myocardial infarctions, cerebral vascular accidents, kidney failure, and other organ failure as a result of microvascular thrombi and ischemia. The thrombi that accumulate in TTP are mostly platelets and do not include fibrin which differentiates TTP from DIC (Strecker-McGraw & Mark Andrew, 2011). The microvascular thrombi cause red blood cells to become injured and the result is hemolytic anemia without red cell antibodies (negative DAT/direct Coombs' test) and the presence of schistocytes, or fragmented red blood cells (Strecker-McGraw & Mark Andrew, 2011). Therapy with plasma exchange as soon as possible is recommended to replace the ADAMTS-13 and reduce the antibodies associated with its destruction (Kappler et al., 2014). Platelet transfusion in the setting of thrombocytopenia in patients with TTP is generally contraindicated and has been historically associated with an increase in mortality, although one recent retrospective study concluded that patients who received platelet transfusions did not have an increased risk of death as a result of the transfusions (Otrock, Liu, & Grossman, 2015).

Implications for Nursing Care

Nursing care must be directed at frequent assessment of patient symptoms, prevention of bleeding, infection, and supportive care. Careful monitoring of neurologic, cardiac and renal function as well as pain patterns and even slight changes in assessment criteria must be reported. Pharmacologic therapy may include corticosteroids, immune suppressing medications, and blood pressure regulators. Refractory patients may receive treatment with rituximab infusions, which requires careful management and close monitoring for reactions. Blood transfusions may be indicated for anemia or platelet products for bleeding may be used. Central venous access is often used for plasma exchange therapy and can be associated with bleeding and infection. Pain control and symptom management associated with widespread microvascular thrombi is important.



Conclusions

TTP is a challenging and dangerous disorder that requires prompt recognition and treatment. The recent discovery of the ADAMTS-13 deficiency and increased availability of plasma exchange therapy has greatly increased an individual's chance of surviving a TTP diagnosis. Recognizing the differences in the microangiopathy disorders can assist clinicians in initiating the proper treatment for these patients. Diagnosing and treating TTP would be a significant responsibility, especially because successful identification and treatment of a disorder like TTP can save someone's life.

References

- Kappler, S., Ronan-Bentle, S., & Graham, A. (2014). Thrombotic microangiopathies (TTP, HUS, HELLP). *Emergency Medicine Clinics of North America*, 32, 649-671. <http://dx.doi.org.proxy.lib.ohio-state.edu/10.1016/j.emc.2014.04.008>
- Konkle, B. A., Hauser, S., Longo, D., Jameson, J. L., & Loscalzo, J. (2015). Disorders of platelets and vessel wall. In D. Kasper & A. Fauci (Authors), *Harrison's Principles of Internal Medicine* (19th ed.). doi:<http://accessmedicine.mhmedical.com.proxy.lib.ohio-state.edu/content.aspx?bookid=1130&Sectionid=79732426>.
- Otrock, Z. K., Liu, C., & Grossman, B. J. (2015). Platelet transfusion in thrombotic thrombocytopenia purpura. *Vox Sanguinis*. doi:10.1111/vox.12274
- Rosove, M. (2014). Thrombotic microangiopathy. *Seminars in Arthritis and Rheumatism*, 43, 797-805. <http://dx.doi.org.proxy.lib.ohio-state.edu/10.1016/j.semarthrit.2013.1.004>
- Strecker-McGraw, M., & Mark Andrew, W. (2011). Chapter 41: Hematologic emergencies. In C. K. Stone & R. L. Humphries (Authors), *Current Diagnosis & Treatment Emergency Medicine* (7th ed.). The McGraw Hill Companies. doi:<http://accessmedicine.mhmedical.com.proxy.lib.ohio-state.edu/content.aspx?bookid=385&Sectionid=40357257>.
- Strobel, A., Gingold, D. B., & Calvello, E. J. (2014). TTP presenting as refractory hypoglycemia in a patient with thromboangiitis obliterans. *American Journal of Emergency Medicine*, 32, 1554.e5-1554.e7. <http://dx.doi.org.proxy.lib.ohio-state.edu/10.1016/j.ajem.2014.04.044>
- Trachtman, H. (2013). HUS and TTP in children. *Pediatric Clinics of North America*, 60, 1513-1526. <http://dx.doi.org.proxy.lib.ohio-state.edu/10.1016/j.pcl.2013.08.007>

Additional Sources

- Al-Nouri, Z. L., Reese, J. A., Terrell, D. R., Vesely, S. K., & George, J. N. (2015). Drug-induced thrombotic microangiopathy: A systemic review of published reports. *Blood*, 125(4), 616-618. doi:10.1182/blood-2014-11-611335
- Norris, M., Mesica, F., & Remuzzi, G. (2012). STEC-HUS, atypical HUS and TTP are all diseases of complement activation. *Nature Reviews Nephrology*, 8, 622-633. <http://dx.doi.org.proxy.lib.ohio-state.edu/10.1038/nrneph.2012.195>
- Sayani, F. A., & Abrams, C. S. (2015). How I treat refractory thrombotic thrombocytopenia purpura. *Blood*, 125(25), 3860-3868. doi:10.1182/blood-2014-11-551580



OTTERBEIN UNIVERSITY